



## Histomorphological Analysis of Testicular Lesions

Hemavathi Reddy<sup>1\*</sup>, Inamdar S.S.<sup>2</sup>, V.D. Doble<sup>3</sup>, Prabhu M.H.<sup>4</sup>.

<sup>1</sup>P G Student, Department of Pathology, S.N. Medical College & Hospital, Navanagar, Bagalkot, Karnataka, India

<sup>2</sup>Professor, Department of Pathology, S.N. Medical College & Hospital, Navanagar, Bagalkot, Karnataka, India

<sup>3</sup>Professor & Head, Department of Pathology, S.N. Medical College & Hospital, Navanagar, Bagalkot, Karnataka, India

<sup>4</sup>Associate Professor, Department of Pathology, S.N. Medical College & Hospital, Navanagar, Bagalkot, Karnataka, India

### ARTICLE INFO

#### Research Article

Received 01 Jan. 2015

Accepted 13 Feb. 2015

#### Corresponding Author:

**Hemavathi Reddy**

P G Student, Department of Pathology, S.N. Medical College & Hospital, Navanagar, Bagalkot, Karnataka, India

Email: drsms70@gmail.com

### ABSTRACT

**Background:** As an organ testes are situated outside the body, they are more vulnerable to blunt trauma, torsion and testicular cancer is an extremely serious condition. Testis is affected by both non neoplastic and neoplastic conditions

**Non neoplastic conditions:** Non-neoplastic causes include cryptorchid testis, testicular torsion, testicular atrophy, epidermoid cysts and infections of testis like tuberculosis, infertility, malakoplakia and vasculitis.

**Neoplastic conditions:** Testicular tumors are rare, these neoplasms span an amazing gamut of anatomic type, contribute for 1-2 % of all malignant tumors and most common malignancy in men in the 15 to 35 year of age group and have a higher percentage of cure rates when diagnosed and treated earlier in life.

**Objectives of the study:** To study various lesions of testis, there clinical mode of presentation and histologic grading in case of cancer.

**Methods:** Descriptive time bound study done at the department of pathology from July 2012 to June 2014.

**Results:** Studying of 100 cases of testicular lesions showed 86% were non neoplastic and 14% were neoplastic. The highest incidence was 1<sup>st</sup> decade (22%) followed by 4<sup>th</sup> decade (20%). Youngest patient is 13 yr old and oldest is 80 yrs old.

**Conclusion:** Studying 100 cases of testicular specimens gives following spectrum of lesions. Testicular swelling was the main chief complaint and left side testis affected more with an incidence 45%. In lesions studied 86% Non neoplastic & 14% Neoplastic. Testicular torsion was the most common benign lesion affected. Seminoma was the most common tumour with incidence of 50% diagnosed in malignant lesions

**Key words:** Undescended testis, testicular torsion, orchitis, neoplasms of testis.

© WWW.IJPBA.IN, All Right Reserved.

### INTRODUCTION

Testis is a male gonad, it is homologous with the ovary of the female genital system and it is a unique and important organ of male reproductive system.<sup>1</sup> The primary functions of the testes are to produce sperm (spermatogenesis) and to produce androgens, primarily testosterone.<sup>2</sup>

Testis is affected by both non-neoplastic and neoplastic condition. Non-neoplastic causes include cryptorchid testis, testicular torsion, testicular atrophy, epidermoid cysts, infections of testis like tuberculosis, infertility<sup>3</sup>, malakoplakia and vasculitis. Atrophy of testis may result from a large variety of causes mainly orchitis of testis by mumps<sup>4</sup>, liver cirrhosis<sup>5</sup>, administration of estrogens, radiation exposure, chemotherapy and exposure to environmental toxin. Testicular atrophy affects 5% of AIDS patients.<sup>3</sup> Infarct of testis is usually result from

torsion of the spermatic cord it may also occur due to venous thrombosis secondary to pyogenic epididymoorchitis.<sup>3</sup> Tuberculosis, atypical mycobacteriosis, leprosy, sarcoidosis and syphilis and chrons disease can involve testis.<sup>3</sup>

Testicular tumours, although relatively rare, are the most common malignancy in men of 15-35 years. Cancers of testis usually found in the young adults are less than 1% of all malignancies in males. The incidence of this neoplasm in western countries is rising in the past 50 yrs.<sup>6</sup> Cancers of testis is more common in whites worldwide, with Hispanics and Asians at intermediate risk and blacks at the lower risk.

**AIMS AND OBJECTIVES:** To study various lesions of surgically removed testicular specimen, there clinical

mode of presentation and histologic grading in case of testicular carcinoma.

**MATERIAL AND METHODS**

Present study is the descriptive study of the gross and histopathological findings of surgically removed testis in 100 specimens received in the department of pathology and tertiary health care centre over a period of 2 years that is from July 2012 to June 2014.

All operated cases included. The testicular specimens received were processed according to the standard procedure, did paraffin fixation and the specimen was examined grossly and necessary sections were taken. These findings were then correlated with clinical diagnosis.

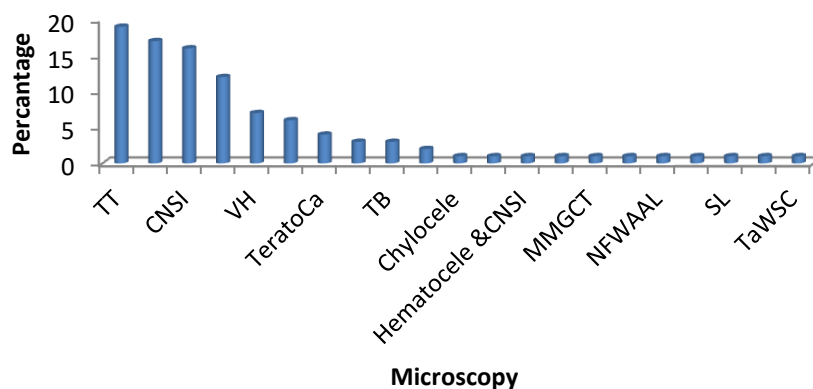
**RESULTS**

Study of 100 cases of testicular specimens analyzed.

Table 1: Age distribution of patients studied

Age in years	No. of patients	%
11-20	22	22.0
21-30	17	17.0
31-40	16	16.0
41-50	20	20.0
51-60	17	17.0
61-70	7	7.0
>70	1	1.0
Total	100	100.0

92% of patients fall into the age group 11-60 yrs. Among 100 cases of testicular lesions studied 86% were benign & 14% malignant lesions.



Graph No 1: Microscopy findings of patients studied

Microscopical diagnosis of all 100 cases were analysed individually, among these lesions testicular torsion was the highest with 19 % followed by testicular atrophy 17% among non neoplastic lesions and in malignant lesions seminoma was the highest 6% followed by teratocarcinoma4%.

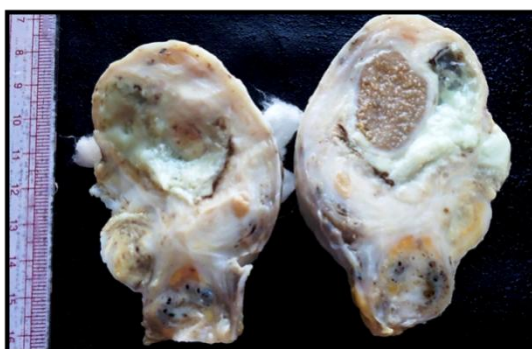


Fig 1: Testicular abscess

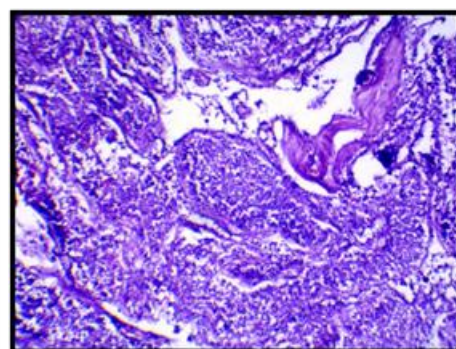


Fig 2: Florid infiltration of seminiferous tubules by ClCl. H&E, 400X.



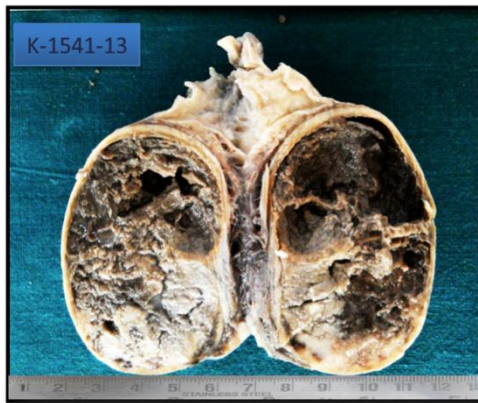

Fig 3: Terato Carcinoma

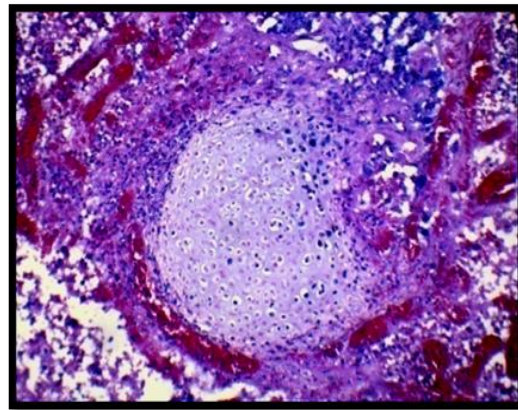


Fig 4: Foci of cartilage with areas of hemorrhage & necrosis. H&E, 100X.

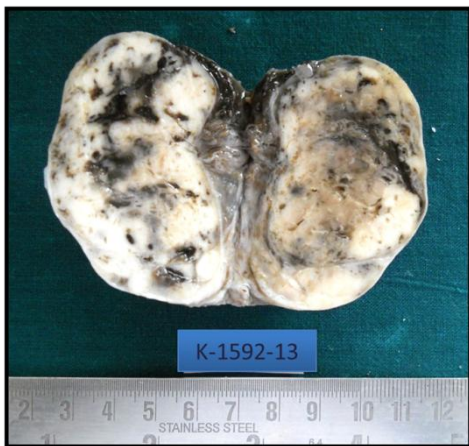

Fig 5: Malignant mixed germ cell tumour.

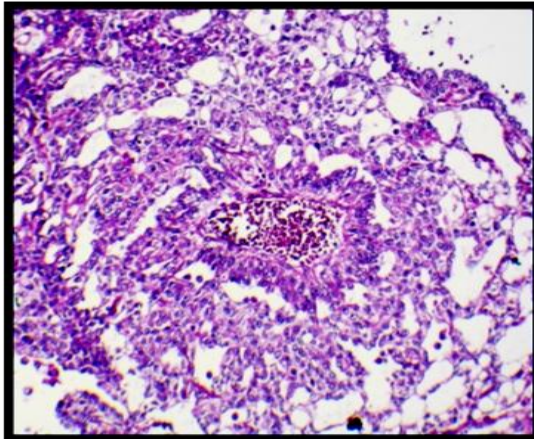


Fig 6: Schiller duval body. H&E, 100X.

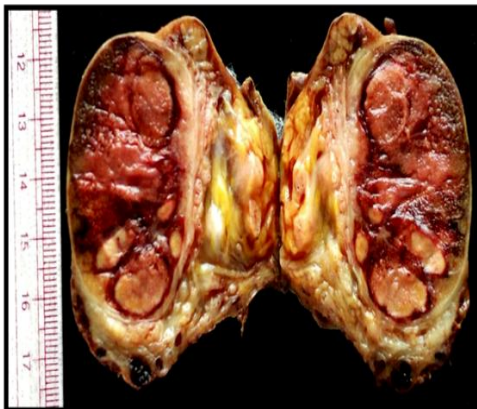


Fig: 7 Gross picture of Seminoma

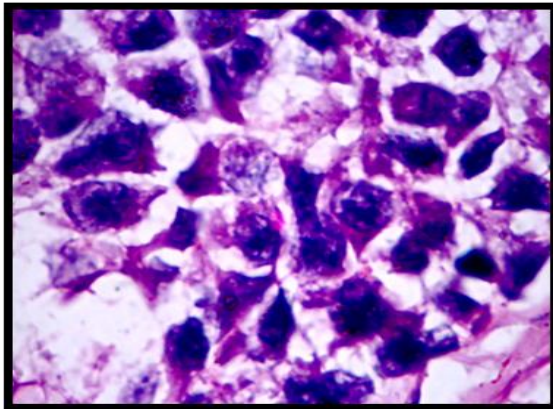


Fig: 8 Round shaped tumour cells having abundant cytoplasm, sharp membrane, centrally placed nucleus & clumped chromatin. H&E, 400X.

## DISCUSSION

Testis is affected by both Non neoplastic and Neoplastic lesions at any age group, but Neoplastic lesions affected in 2<sup>nd</sup> decade with an incidence of 50%.

Commonest mode of presentation is scrotal swelling, testicular swelling and pain, affected age group ranges from 11-80 yrs.

Age group of patients studied among Neoplastic lesions in 3<sup>rd</sup> decade was 50% in present study which were 39.7% of Syed Q et al and 32% of Deotra et al studies.

Relative frequency of testicular torsion with an incidence of 19% in present study and which were 10.1%, 13.1% and 48% in studies done by Arun Srinivasn et al, Syed Ali Rizvi et al and Rampaul MS study respectively.

Relative frequency of testicular tumours among cancers by different authors compared with present study and it was correlated

**Table No 2: Relative frequency of testicular tumours among cancers by different authors.**

Author	Year	Percentage
Dean <sup>7</sup>	1935	2.09
Gilbert & hamilton <sup>8</sup>	1940	1.5-2.0
Sameer <sup>9</sup>	1948	0.5
Dixon & Moore <sup>10</sup>	1952	0.64
Prossor <sup>11</sup>	1964	2.0
Krishnabhargava & Govind Reddy <sup>12</sup>	1968	2.73
Present study	2014	1.4%

Comparison of chief complaint of testicular swelling of lesions in the present study was 97% , it was 80% and 60% in studies by Robson et al and Deotra A et al respectively.

Frequency of right side lesions in the present study is 42% and 60% in Deotra A et al study.

### CONCLUSION

100 cases of testicular lesions were studied for a period of 2 yrs youngest patient 13 years old and oldest was 80 years. Testicular swelling was the main chief complaint. Left side testis affected more with an incidence of 45% in lesions studied 86% Non neoplastic & 14% Neoplastic testicular torsion was the most common benign lesion seminoma was the most common tumour study of both Non neoplastic and Neoplastic lesions of testis is important for pathologists because grossly identifiable benign pathology may harbor in focus of malignancy. Various studies have analyzed the importance of histologic grade (WHO classification) as a prognostic factor in carcinoma of the testis, which is a very important, and effective for the management of testicular carcinoma and prevent its spread.

### REFERENCES:

1. Chaurasia BD. Male Reproductive System. In: Human Anatomy, Volume 2. 5<sup>th</sup>ed. New Delhi: CBS Publishers and Distributors; 2010.p.210-217.
2. Jain AK. Male Reproductive System. In:Textbook of Physiology, Volume II. 5<sup>th</sup>ed. New Delhi: Avichal Publishing Company; 2012. p.806-817.
3. Juan R. Male reproductive system. In: Rosai and Ackerman's Surgical Pathology, Volume 1. 10<sup>th</sup> ed. St. Louis: Elsevier; 2011.p.1334-1374.
4. Gall EA. The histopathology of mumps orchitis. Am J Pathol 1947;23:637-652.
5. Bennett HS,Baggenstoss AH, Butt HR. The Testis and Prostate of Men who die of cirrhosis of liver. Am J Clin Pathol 1950; 20:814-828.
6. Bergstorm et al.Testicular cancer in nine European countries. Int J Cancer 1996; 59:33-38.
7. Dean et al. study testicular tumours. J Arm Med Assoc 1935;105(24):1965-1972.
8. Gilbert JB, Hamilton JB. Studies in malignant testis tumours. Surg Gynecol Obstet 1940; 71:731-743.
9. Sameer et al. Testicular tumour A review of 83 cases. The Lancet 1948;252:517-554.
10. Dixon FJ, Moore RA. Tumour s of male sex organs. In: atlas of tumour pathology, series 1, section VIII, fascicles 31b and 32. Washington. D.C.1952,Armed forces of institute of pathology.
11. Prossor et al. Tumours of testis. JR Coll Surg edinb.1964;9:85-105.
12. Krishnabhargava , Govindreddy. Clinicopathologic study of 82 cases of testicular tumours 1968; 19 (11):1655-1665.